

Effect of polaprezinc on healing of acetic acid-induced stomatitis in hamsters

Manuscript received December 3rd 1999, Revised January 14th, 2000; Accepted January 14th, 2000.

Shirou Katayama, Kenji Nishizawa, Masaaki Hirano

Department of Pharmacy, Medical School Hospital, Sendagi 1-1-5 Bunkyo-ku, Tokyo 113-8602, Japan

Shigeo Yamamura, Yasunori Momose

Department of Clinical Pharmacy, School of Pharmaceutical Sciences, Toho University, Miyama 2-2-1, Funabashi, Chiba 274-8510, Japan

ABSTRACT Purpose: The purpose of this work was to investigate the potential effectiveness of polaprezinc in the treatment of stomatitis. Its effect on oral mucous membrane lesions was studied focusing on acetic acid-induced stomatitis in an animal model. **Method:** Stomatitis was induced in hamsters by local injection of 30 μ L of 10% acetic acid solution into both cheek pouches. Change of the size of the acetic acid-induced white lesion caused by polaprezinc injection was compared with that of control (water injection). The process of healing of damaged membrane was also investigated histopathologically. Selective adhesion of polaprezinc on mucous membrane was studied using color development by complexation between zinc and dithizone. **Results:** On day 4 after acetic acid injection, round white lesions were observed in the central area of both pouches. Observation on days 7, 10, and 14 showed that the size of the lesions decreased with time. Comparison with the control group of animals, in which healing took place naturally, showed that daily administration of polaprezinc (10 mg/kg) applied to the cheek pouches significantly promoted healing of the lesion from day 7 onward. Histopathological investigation of the mucous membrane in the cheek pouches 7 days after the induction of stomatitis by acetic acid injection

showed thickening, and cell damage was evident. In the group of animals treated with polaprezinc, the thickening of the mucous membrane was less than that in animals of the group receiving no treatment and regeneration of damaged tissue was observed after 6 days of polaprezinc treatment. **Conclusion:** Polaprezinc is an effective treatment in this animal model of acetic acid-induced stomatitis. This suggests that the drug may be useful in promoting healing of stomatitis in the clinical setting. Extrapolating these to humans suggests that the drug has healing effect to severe stomatitis induced by anticancer drug therapy.

INTRODUCTION

Stomatitis may be caused either directly or indirectly by anticancer drug administration, irradiation or bacterial infection, resulting in considerable pain regardless of the severity of the symptoms (1). Current methods of prevention and treatment of stomatitis in the clinical setting include treatment of the oral mucosa with bactericidal agents, administration of inhibitors of free-radical production, local anesthetic drugs, and anti-inflammatory/analgesic drugs. However, these methods are not all satisfactory, and the condition recurs in a significant number of patients after the lesions have healed (2, 3).

Polaprezinc is a zinc-L-carnosine complex (4), and an anti-ulcer agent which protects the mucous membrane, chiefly through its antioxidant effect (5).

Corresponding author: Shirou Katayama, Department of Pharmacy, Medical School Hospital, Sendagi 1-1-5 Bunkyo-ku, Tokyo 113-8602, Japan.
Katayama_Sirou/hosp_ph@nms.ac.jp

It promotes healing through a mechanism involving insulin-like growth factor I (IGF-I) (6). Polaprezinc may be effective in the treatment of stomatitis, since it has been suggested that free radicals also play a role in the onset of this condition (7). As polaprezinc has been shown to promote healing, it may have a positive effect on the repair of mucous membrane lesions. We have reported that a mixture of polaprezinc and sodium alginate was useful in the treatment of patients with severe stomatitis (8).

In this study, the effect of polaprezinc on oral mucous membrane lesions was studied, focusing on acetic acid-induced stomatitis in an animal model to investigate the potential effectiveness of polaprezinc in treatment of stomatitis.

MATERIALS AND METHODS

Animals

Four-week-old male Golden Syrian hamsters weighing approximately 50 g were used after acclimatization for at least 4 days. Six or 7 animals were used for experiments in each group.

Reagents

Polaprezinc (Hamari Pharmaceuticals Japan) was suspended in saline solution at a concentration of 10 mg/mL. A volume of 1 mL/kg (10 mg/kg as polaprezinc) of the suspension was applied to the intraoral lesions. The test substance was stored in a cool place until use. All of the reagents used were analytical reagent grade. Dithizone solution was prepared by dissolving 1g of dithizone in 10 mL of 99.5% ethanol, adding 2 mL of 25% ammonia solution and dilution to 200 mL with water.

Induction of stomatitis using acetic acid

The stomatitis model was established using the method of Tsukimi (9). Briefly, under pentobarbital (50 mg/kg, i.p.) anesthesia the cheek pouches of the hamsters were extended outside the oral cavity. The central portion of the pouch was held with ring tweezers with an inside diameter of 6 mm, and a

micro syringe was used to locally inject 30 μ L of 10% acetic acid solution under the mucous in the section held by the ring tweezers. The cheek pouches were then returned to the oral cavity, and the animals were returned to their cages. Animals were killed with ether on days 4-14 after induction of stomatitis. The cheek pouches were then resected and fixed in 2% formalin, and the area (mm^2) of each lesion was measured under a stereoscopic microscope. Polaprezinc was applied to the cheek pouch lesions once a day for 3-13 days from the day following induction of stomatitis. Saline was applied to the lesions in the control group.

Histopathological investigation

The cheek pouches of hamsters 7 days after local injection of acetic acid solution were resected and fixed in 10% phosphate buffer-formalin solution. After washing by ethanol, and xylene several times, the tissue was filled in paraffin. After solidified, paraffin sections were prepared using a previous method. After staining with hematoxylin and eosin, the sections were observed under a microscope.

Adhesiveness of polaprezinc on the mucous membrane

Polaprezinc solution (10 mg/kg) was applied to the cheek pouches 4 days after local injection of acetic acid solution. Then 0.5, 1 and 3 h after application, animals were sacrificed, the cheek pouches were resected and washed with saline solution. Zinc adhering to the mucous membrane of the cheek pouch was detected by reaction with 0.5%-dithizone solution.

Statistical analysis

The results are shown as mean \pm standard error. The significance of differences between the groups was tested using the unpaired Student's t-test (at $\alpha = 0.05$). A p-value for rejection of the null hypothesis was 0.01 or 0.001.

RESULTS

Effect of polaprezinc on acetic acid-induced stomatitis in hamsters

Round, white lesions ($36.9 \pm 4.2 \text{ mm}^2$) were observed in the central area of both cheek pouches 4 days after local injection of 30 μL of 10% acetic acid solution into each of the cheek pouches (Figure 1). Observation on days 7, 10, and 14 showed that the lesions decreased in size with time (day 7: $11.8 \pm 1.2 \text{ mm}^2$; day 10: $6.6 \pm 0.5 \text{ mm}^2$; day 14: $2.4 \pm 0.2 \text{ mm}^2$). Comparison with the natural healing that occurred in the control group revealed that daily intraoral application of polaprezinc (10 mg/kg) tended to accelerate healing (lesion area: $33.1 \pm 3.1 \text{ mm}^2$) on day 4, and significantly accelerated healing from day 7 onward (day 7: $6.3 \pm 0.4 \text{ mm}^2$, $p < 0.01$; day 10: $2.5 \pm 0.5 \text{ mm}^2$, $p < 0.001$; and day 14: $1.2 \pm 0.2 \text{ mm}^2$, $p < 0.001$).

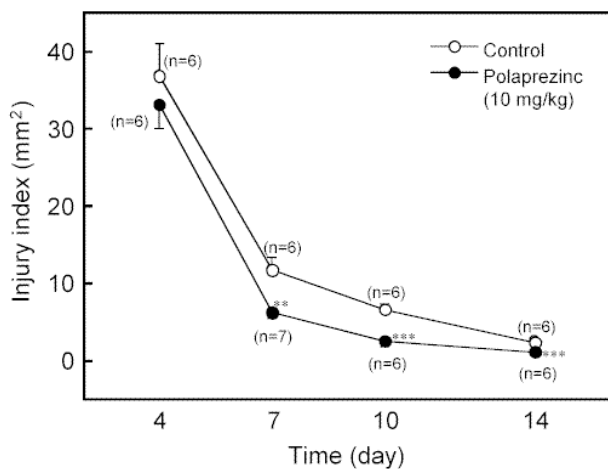


Figure 1 Changes in the area of the lesion in hamsters with acetic acid-induced ulcers. Each point represents the mean \pm S.E. for 6-7 animals. Significant difference from the control: **, $p < 0.01$, ***, $p < 0.001$ Student's t-test). Key: \circ , control; \bullet , polaprezinc (10mg/kg).

Histopathological observation of acetic acid-induced stomatitis

Figure 2 shows photographs of the cheek pouch stomatitis induced by acetic acid. Compared with the normal mucous membrane, thickening and damage of the mucous membrane were found in both the

polaprezinc-treated and the untreated (control) groups 7 days after local injection of acetic acid solution. In the case of animals treated with polaprezinc for seven days, although thickening of the mucous membrane was still observed, and extent of damage produced by acetic acid treatment was found to be less than in the unreacted control group, and regeneration of damaged tissue was observed following polaprezinc treatment.

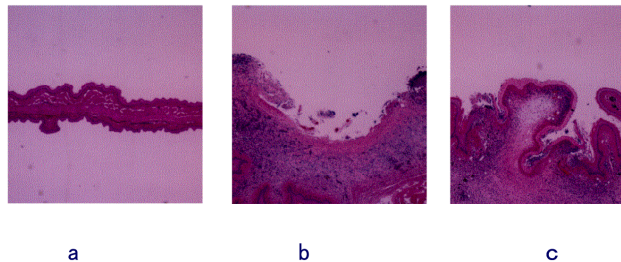


Figure 2 Photographs of membrane of the cheek pouch stomatitis induced by acetic acid (7 days post acetic acid-induced ulceration). a, normal membrane; b, untreated membrane (7 days after injection of acetic acid); c, polaprezinc treatment membrane (7 days after injection of acetic acid). (H.E. staining, original magnification 20 X).

Adhesiveness of the polaprezinc on the mucous membrane of the cheek pouch

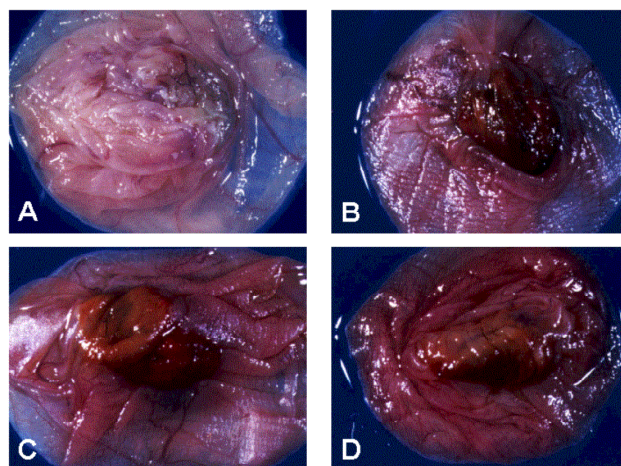


Figure 3 Photographs of adhesion of zinc to the mucous membrane of the cheek pouch at sites of ulcers induced by acetic acid. A, control (before treatment of polaprezinc); B, after 0.5h; C, after 1h; D, after 3h. Polaprezinc adhered on the membrane is indicated by color development with complexation between zinc and dithizone.

Figure 3 shows photographs demonstrating the adhesion of zinc to the mucous membrane of the cheek pouch at sites of stomatitis induced by acetic acid injection. Polaprezinc adhered on mucous membrane is detected by color development with complexation between zinc and dithizone. As shown in Figure 3-A, no adhesion of zinc to normal mucous membrane was found. Even though no adhesion to normal mucous membrane was found, adhesion of zinc to damaged mucous membrane was evident 0.5, 1 and 3 h after application of polaprezinc.

DISCUSSION

Repeated application of polaprezinc at 10 mg/kg to the inside of the cheek pouches of hamsters resulted in significant acceleration of healing when compared with natural healing in this animal model of acetic acid-induced stomatitis. In the histopathological investigation, the thickening of the mucous membrane was observed to be less than in the untreated control group, and regeneration of damaged tissue was observed following polaprezinc treatment. These results suggest that polaprezinc adhered to damaged mucous membrane and accelerated healing of damaged tissues. In the previous report, high effectiveness of polaprezinc-sodium alginate suspension has been demonstrated in patients with severe gingivostomatitis (8).

Various mechanisms are involved in the onset of stomatitis. The disease is particularly common after irradiation or after administration of anticancer drugs. The mechanism is believed to involve direct or indirect attack of the oral mucosa by free radicals generated by irradiation or anticancer drugs (7). In such patients, the stomatitis is treated with the xanthine oxidase inhibitor allopurinol, to inhibit the production of free radicals (7). This suggests that drugs with antioxidant activity may be effective in the treatment of stomatitis. In the present study, stomatitis was induced in the cheek pouches of hamsters using acetic acid, an ulcer model commonly employed in animal studies of ulcers. The acetic acid ulcer model is frequently used to evaluate the therapeutic effects of antiulcerative agents because the lesions share many of the histopathological

characteristics of stomach ulcers in humans (9). One of the characteristics of this model is marked inflammatory cell infiltration around the ulcer, and it has been suggested that free radical reactions caused by these inflammatory cells may delay ulcer healing (10). The model of acetic acid-induced stomatitis used in the present study therefore appears to resemble clinical stomatitis in terms of the involvement of free radical reactions in the onset of the condition and the delayed healing of the associated lesions.

Polaprezinc is an antiulcer agent that protects the mucosa, mainly through its antioxidant effects (10), and it accelerates healing via a mechanism involving IGF-I (11). Polaprezinc has been reported to adhere selectively to the damaged region in the case of gastric ulcers. (12). In the present study, polaprezinc showed selective adhesion, at least, for 3 h to the oral mucous membrane at the site of damage induced by acetic acid. This result suggests a possible link between the marked healing effects of polaprezinc and its antioxidant activity. This may be responsible for the observed protection of the mucosa from damage incurred through free-radical reactions, as in the case of gastric ulcers. Acceleration of healing via IGF-I may also occur simultaneously. In the case of clinical stomatitis, it is assumed that polaprezinc would suppress the free-radical reactions responsible for delayed healing through its antioxidant effects, and at the same time it would have a therapeutic effect by promoting healing.

In conclusion, polaprezinc showed marked effects on acetic acid-induced stomatitis in an animal model. The results indicate that polaprezinc has a healing effect on oral mucous membrane lesions. It has been reported previously that polaprezinc suspensions showed a marked therapeutic effect in patients with severe stomatitis by topical administration in mouth cavity (8). The clinical effect of polaprezinc for stomatitis was observed as rapidly as within 5 days in many cases. This therapeutic effect seems to be due to the healing action of polaprezinc on the oral mucous membrane and this drug may be useful for the treatment of stomatitis at the clinical level. The result of animal study in the present investigation

indicates that polaprezinc has healing effect of damaged mucous membrane and the effect may be expandable to human gingivostomatitis.

REFERENCES

1. Sonis, S.T., Sonis, A.L., Liederman, A. (1978) Oral complications in patients receiving treatment for malignancies other than of the head and neck. *J. Am. Dent. Assoc.* 97: 468-472
2. Ichimura, K. (1985) Local treatment of stomatitis. *JOHNS* 1: 301-304
3. Oka, H. (1984) Gastrointestinal disorders II-4-1. Stomatitis, *Clinic All-Round* 1984; 33: 2002-2005
4. Matsukura, T., Takahashi, T., Nishimura, Y., Sawada, M., Shibata, K. (1990) Characterization of crystalline L-carnosine Zn(II) complex(Z-103), a novel anti-gastric ulcer agent: tautomeric change of imidazole moiety upon complexation. *Chem. Pharm. Bull.* 38: 3140-3146
5. Yoshikawa, T., Naito, Y., Tanigawa, T., Yoneta, T., Kondo, M. (1991) The antioxidant properties of a novel zinc-carnosine chelate compound, N-(3-aminopropionyl)-L-histidinato zinc. *Biochim. Biophys. Acta* 1115: 15-22
6. Watanabe, S., Wang, X. E., Yoneta, T., Seto, K. Sato, N. (1997) Zinc and its derivative accelerated gastric wound healing through the production of insulin-like growth factor from fibroblasts in a culture cell model. *Gastroenterology* 112 (abstr), A327
7. Porta, C., Moroni, M., Nastasi, G. (1994) Allopurinol mouthwashes in the treatment of 5-fluorouracil-induced stomatitis. *Am. J. Clin. Oncol.* 17: 246-247
8. Katayama, S., Ohshita, J., Sugaya, K., Hirano, M., Momose, Y., Yamamura, S. (1998) New medicinal treatment for severe gingivostomatitis. *Int. J. Mol. Med.* 2: 675-679
9. Tsukimi, Y., Okabe, S. (1994) Validity of kissing gastric ulcers induced in rats for screening of antiulcer drugs. *J. Gastroenterol. Hepatol.* 9: S60-65
10. Okabe, S., Pfeiffer, C. J. (1972) Chronicity of acetic acid ulcer in the rat stomach. *Digest. Dis.* 17: 619-629
11. Naito, Y., Yoshikawa, T., Matsuyama, K., Yagi, N., Arai, M., Nakamura, Y., Nishimura, S., Yoshida, N., Kondo, M. (1995) Effects of oxygen radical scavengers on the quality of gastric ulcer healing in rats. *J. Clin. Gastroenterol.* 21: S82-86
12. Aita, H., Yoneta, T., Hori, Y., Morita, H., Seto, K., Mera, Y., Arai, K., Toyama, S., Tagashira, E. (1992) Selective binding of Z-103 to the ulcer region in rats with acetic acid-induced gastric ulcers. *Ther. Res.* 13: 2413-2422