

Neuromuscular Electrical Stimulation and Exercise for Reducing Trapezius Muscle Dysfunction in Survivors of Head and Neck Cancer: A Case-Series Report

Evan R.L. Baldwin, MSc, PT;* Terri D. Baldwin, MSc, PT;† Josh S. Lancaster, MSc, PT;‡ Margaret L. McNeely, PT, PhD;§¶ David F. Collins, PhD**

ABSTRACT

Purpose: Damage to the spinal accessory nerve (SAN) can result in denervation of the trapezius muscle in patients undergoing surgery for head and neck cancer. Trapezius denervation leads to muscle weakness and dysfunction that, for some patients, persists despite the return of conduction along the SAN. This prospective case series describes an intervention involving a combination of a novel type of neuromuscular electrical stimulation (NMES) with bilateral exercise. **Methods:** Three survivors of head and neck cancer participated in the 6-week program. NMES was applied over the region of the SAN on the affected side while subjects performed bilateral voluntary scapular retraction and elevation exercises against resistance. The NMES was delivered using relatively wide pulse widths and high frequencies to enhance the electrically evoked sensory volley and was triggered by the onset of trapezius muscle activity on the non-affected side. Shoulder range of motion (ROM) assessments and patient-rated outcomes were administered at baseline and 6 weeks. **Results:** All patients showed improvements in shoulder flexion and abduction ROM and reported reductions in pain and disability. **Conclusions:** This combination of NMES and bilateral exercise may prove to be an effective component of a comprehensive shoulder rehabilitation program for patients with persistent trapezius muscle dysfunction as a result of SAN damage.

Key Words: electric stimulation; head and neck neoplasms; muscular atrophy; muscle contraction; rehabilitation.

RÉSUMÉ

Objectif : Des dommages au nerf spinal accessoire (NSA) peuvent donner lieu à une dénévation du muscle trapèze chez les patients qui subissent une intervention chirurgicale pour un cancer au cou ou à la tête. La dénévation du trapèze provoque une faiblesse musculaire et une dysfonction qui, chez certains patients, persistent malgré le retour d'une conduction du NSA. Cette série de cas prospectifs décrit une intervention qui met à contribution une nouvelle technique de stimulation neuromusculaire électrique (NMES), associée à des exercices bilatéraux. **Méthode :** Trois personnes ayant survécu à des cancers au cou ou à la tête ont pris part à un programme de six semaines. La NMES a été utilisée sur toute la région du NSA, sur le côté touché, pendant que les sujets exécutaient des mouvements de rétraction bilatérale scapulaire volontaires et des exercices d'élevation avec résistance. La NMES a été administrée en utilisant des durées d'impulsions relativement longues et des fréquences élevées pour évoquer, sous forme électrique, un élan (volée) sensoriel; la NMES était activée dès le début de l'activité musculaire du trapèze du côté non affecté. Les évaluations de l'amplitude du mouvement (ADM) et l'évaluation des résultats par les patients ont eu lieu au départ, puis six semaines plus tard. **Résultats :** Tous les patients ont démontré des améliorations dans l'ADM en flexion et abduction de l'épaule, et tous ont fait part de diminutions de la douleur et de l'incapacité. **Conclusions :** La combinaison de NMES et d'exercices bilatéraux pourrait s'avérer efficace dans le cadre d'un programme complet de réadaptation de l'épaule pour les patients aux prises avec une dysfonction persistante du muscle trapèze à la suite de dommages subis au NSA.

Shoulder function is often compromised in patients who have undergone surgery for head and neck cancer.¹⁻⁶ The impairment may result from traction and devascularization of the spinal accessory nerve (SAN) during the neck dissection procedure, which can denervate the trapezius muscle.^{1,5} The resulting paralysis or weakness of the trapezius can lead to abnormal shoulder biomechanics, shoulder droop, anterior displacement of the humeral head, scapular winging, and pain, all of which negatively

affect quality of life (QOL).^{4,5} At present, traditional physical therapy interventions focus on pain management, range of motion (ROM), and progressive resistance exercise therapy (PRET).^{1,2,6}

In some patients, trapezius muscle dysfunction persists even after conduction along the SAN returns.^{1,3,4} The combination of persistent muscle dysfunction with recovery of transmission along the peripheral nerve presents a challenge for rehabilitation. Traditional physical

From the *Hospital Side Physical Therapy; †CBI Health, Red Deer; ‡Queen Elizabeth II Hospital, Alberta Health Services, Grande Prairie; §Department of Physical Therapy; **Human Neurophysiology Laboratory, Faculty of Physical Education and Recreation, Centre for Neuroscience, University of Alberta; ¶Department of Rehabilitation Medicine, Cross Cancer Institute, Alberta Health Services, Edmonton, Alta.

Correspondence to: Dr. David F. Collins, E-488 Van Vliet Centre, University of Alberta, Edmonton, AB T6G 2H9; dave.collins@ualberta.ca.

Contributors: All authors designed the study, collected the data, and analyzed and interpreted the data; drafted or critically revised the article; and approved the final draft.

Competing Interests: None declared.

Physiotherapy Canada 2012; 64(3):317-324; doi:10.3138/ptc.2011-230

therapy treatment approaches may have limited benefit, as the initial nerve injury and prolonged disuse of the affected trapezius muscle may have led to maladaptive changes at the level of the muscle, spinal cord, and brain. At the muscle level, disuse atrophy is a common consequence of peripheral nerve injury;⁷ accordingly, muscle weakness is one component of the reduced trapezius function.⁵ Centrally, a cascade of changes take place in the spinal cord and brain, largely because of decreased activity in neural circuits controlling the affected muscle.⁸ In the spinal cord, changes occur in synaptic connectivity, biophysical properties of spinal neurons, and transmission along reflex pathways.⁸ In the brain, reorganization in the sensorimotor cortex results in less cortical area devoted to the damaged nerve.⁸ Thus, a weakening of pathways between the brain and spinal cord (corticospinal pathways) likely contributes to the persistent trapezius dysfunction.

This case series reports on a combination of a novel form of neuromuscular electrical stimulation (NMES) with bilateral exercise to improve shoulder function in three adults who had surgery for head and neck cancer and presented with chronic trapezius muscle dysfunction despite evidence of conduction along the SAN. NMES and bilateral exercise were chosen to target maladaptive changes in the muscle and central nervous system (CNS) that may account for persistent trapezius muscle dysfunction in these individuals.

METHODS

Case descriptions

Ethical approval for the case series study was granted by the Alberta Cancer Board Research Ethics Committee. Patients were identified following completion of a previous study examining a PRET protocol at the University of Alberta.⁶ Patients were eligible for the current study if they showed evidence of conduction along the SAN but continued to present with ongoing trapezius muscle dysfunction, defined as (a) visible atrophy of the upper trapezius muscle; (b) winging of the scapula with shoulder abduction in the coronal plane; (c) limitation of active shoulder abduction range of motion; and (d) normal passive glenohumeral motion.^{3,5} Four eligible patients were identified from the initial PRET study, three of whom agreed to participate.

Patient 1

Patient 1 was a 45-year-old man with Stage III nasopharyngeal squamous cell carcinoma (SCC). Initial treatment consisted of chemotherapy (cisplatin) and radiation therapy over a 6-week period. Six years later, he was diagnosed with recurrent SCC and underwent a right partial parotidectomy and bilateral neck dissection, followed by post-operative chemotherapy. The neck dissection included right radical neck dissection (dominant

side) sacrificing the jugular vein (JV) and sternocleidomastoid (SCM) muscle and a portion of the SAN. The right SAN was cable grafted using a sensory nerve from the cervical plexus. On the left side, a selective neck dissection of level 1 was performed; no deficits were noted following surgery in the left trapezius muscle. At the time of enrolment (2 years post surgery), he had been following a home-based shoulder exercise program.

Patient 2

Patient 2 was a 56-year-old man with Stage II SCC in the left lateral pharyngeal wall and base of tongue. He underwent surgery including resection of the soft palate, lateral pharyngeal wall, half of the base of the tongue, tonsillar area and bilateral neck dissection. Reconstruction was performed using a left radial forearm free flap. On the right side, a selective neck dissection of levels 1 through 4 was performed, with preservation of the JV, SAN, and SCM and resection of the submandibular gland. On the left (non-dominant) side, an extended neck dissection was performed involving resection of the deep musculature, hypoglossal nerve, and external carotid artery. The left SAN was grafted using the superficial supraclavicular nerve (sensory). Postoperative treatment consisted of chemotherapy (carboplatin) concurrent with radiation therapy. At the time of enrolment (22 months post surgery), he was following a home-based shoulder exercise program.

Patient 3

Patient 3 was a 55-year-old woman with Stage III SCC at the base of the tongue and vallecula. She underwent surgery including resection of the complete base of the tongue, right posterior aspect on the floor of the mouth, right lateral pharyngeal wall and tonsil, right hypoglossal nerve, and bilateral selective neck dissection. A left radial forearm free flap repair was performed to reconstruct the area of resection. Postoperative treatment included chemotherapy (cisplatin) concurrent with radiation therapy. Nine months later, recurrent cancer was found in a lymph node in the right neck, requiring further neck dissection surgery (dominant side) with sparing of the spinal accessory nerve. At the time of enrolment (30 months post surgery), she was continuing with a self-directed shoulder PRET program at a fitness facility.

Clinical impression

Nerve-conduction studies conducted before participation in the current study revealed side-to-side asymmetries in the amplitude of maximal compound muscle action potentials (i.e., maximal M-waves) recorded from the upper portion of the trapezius for all participants. The maximal M-waves showed decrements of 53%, 52%, and 73% on the affected side compared to the unaffected side for Patients 1, 2, and 3 respectively. As all participants were >18 months post surgery, further recovery

Box 1 Features and Rationale for Treatment Approach

| Unique Features of Treatment Approach | Rationale for Treatment Approach |
|--|---|
| NMES applied over the spinal accessory nerve instead of the trapezius muscle | Reduce amount of current required to induce muscle contraction, avoid overflow to other muscles. Address challenges of muscle point stimulation in atrophied trapezius muscle. Maximize the central contribution to electrically evoked contractions. ^{16,18} |
| NMES triggered by the onset of trapezius muscle EMG activity on the non-surgical side | Ensure the coincident timing of activating the motor cortex by voluntary commands and electrically-evoked sensory volley to maximise increases in corticospinal excitability. ^{23,25} |
| Use of wider pulse widths (1 ms) and higher stimulus frequencies (up to 100 Hz) than traditionally used for NMES | Enhance the electrically evoked sensory volley to enhance the central contribution to the electrically evoked contractions ^{16,20,21} and maximize increases in corticospinal excitability. ²² |
| Bilateral exercise | Augment cortical excitability. ^{24,25} |

of the SAN resulting in spontaneous trapezius muscle re-activation was considered unlikely. The combined program of NMES and bilateral exercise was designed to enhance trapezius muscle contractions and increase muscle mass and strength, strengthen corticospinal pathways to trapezius, and lead to an overall improvement in shoulder function.

Examination**Range of motion (ROM)**

Active shoulder flexion and abduction ROM were measured in supine lying by two raters using a universal goniometer at both baseline and 6 week assessments. Standardized procedures were followed to ensure that compensatory movements were not used to attain greater ROM. Both raters assessed ROM of each movement three times, as recommended by Low,⁹ and ROM was expressed as the average of all values. The minimal clinically important difference (MCID) for shoulder flexion and abduction, measured in supine, has been reported to be 12° and 24° respectively when measurements were taken by two raters.¹⁰

Patient-rated outcomes

The Shoulder Pain And Disability Index (SPADI)^{11,12} and the Neck Dissection Impairment Index (NDII)¹³ were completed by each patient at baseline and 6 weeks. The SPADI is completed using a 10 cm visual analogue scale and final scores are converted to total points out of 100. The SPADI consists of five questions related to pain and eight questions related to disability; a lower SPADI score indicates lower perceived pain and disability. The MCID established for the SPADI is a 10-point change in the scale out of 100.¹² The NDII is a 10-item, 5 point scale questionnaire used to determine the long-term effects of neck dissection on quality of life related to shoulder and neck dysfunction.¹³ Each item is rated from 1 to 5; the final score is converted to total points out of 100, where a higher score indicates less impairment. An MCID has yet to be established for the NDII. Both SPADI and NDII were reported to the nearest 0.5 points.

Intervention

The intervention consisted of a novel form of NMES (wide pulse width, high frequency) applied over the SAN on the affected side, combined with bilateral exercise. The rationale for this approach is summarized in Box 1 and described briefly below. Treatment lasted approximately 1 hour, and participants attended 3 sessions per week for 6 consecutive weeks. This timeframe was based on previous research suggesting that programs of 2–8 weeks,¹⁴ 2–3 times per week,¹⁵ are sufficient to produce neuromuscular adaptations from resistance training.

Surface electromyography (EMG)

Self-adhesive Ag-AgCl surface electrodes (2.25 cm²; Vermed, Inc., VT, USA) were placed approximately 1 cm apart over the upper and middle fibres of trapezius bilaterally (see Figure 1). Ground electrodes were placed on nearby bony prominences. EMG data were amplified 1,000×, bandpass filtered (30–1000 Hz) using Grass P511 amplifiers (Astro-Med, RI, USA) and sampled at 2000 Hz using a 12-bit A/D converter (National Instruments Corporation, TX, USA) and custom software.

EMG-triggered neuromuscular electrical stimulation (NMES)

NMES was delivered using a DS7A constant current stimulator (Digitimer, Letchworth Garden City, UK) controlled by computer. NMES activates both motor and sensory axons beneath the stimulating electrodes. The activation of motor axons generates a “volley” of action potentials in motor axons that travels from the stimulation site to the muscle and contributes to the contraction. The activation of sensory axons generates a “sensory volley” that travels to the CNS. NMES was delivered to enhance the activation of sensory axons to maximize the central contribution to the evoked contractions and the effect of the sensory volley on strengthening corticospinal pathways¹⁶ (see Box 1). NMES was applied through two electrodes placed over the SAN at the anterior portion of the upper trapezius on the affected side (see Figure 1). The NMES was applied over the nerve, rather than the muscle belly, to augment the central contribution to

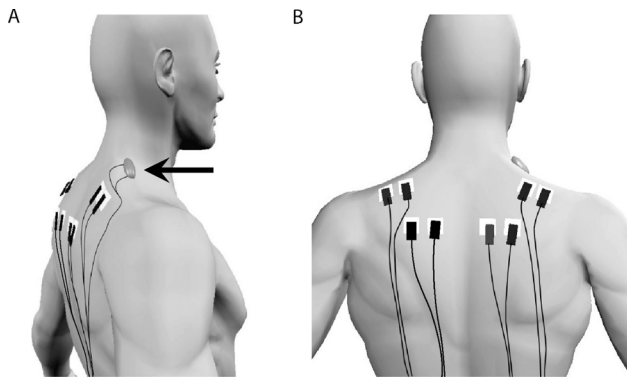


Figure 1 Schematic showing the locations for the stimulation and recording electrodes.

electrically evoked contractions, which may help reduce muscle atrophy.^{17,18} The stimulation location was identified as the site at which single stimuli evoked a contraction at the lowest stimulation intensity. A pulse width of 1ms was chosen over the narrower pulses traditionally used for NMES (100–400 μ s¹⁹) because wider pulse widths preferentially recruit sensory axons and thus send a larger sensory volley to the CNS.²⁰ NMES was delivered for 10 s in a triangular frequency profile, ramping up and down linearly from 35 to 100 to 35 Hz. This pattern incorporates higher stimulus frequencies than typically used for NMES (20–40 Hz¹⁹) to further enhance the effect of the sensory volley on the CNS.^{21,22} To confirm appropriate stimulation location and ensure effective conduction along the motor branch of the SAN, trapezius muscle contractions were identified by palpation and the presence of M-waves in the trapezius was verified by EMG.

During the NMES-assisted exercises, stimulation on the affected side was triggered by the onset of trapezius EMG on the non-affected side. This EMG-triggered NMES ensured the coincident timing of activation of the motor cortex by voluntary commands and the sensory volley generated by the NMES, which has been shown to optimize the NMES-induced strengthening of corticospinal pathways.²³ Trapezius EMG and the timing of the stimulation during shoulder elevation are shown in Figure 2. The trigger level was set using the full-wave rectified EMG from the upper trapezius during elevation exercises (see Figure 2B) and from the middle trapezius during retraction exercises. Stimulation intensity was set to evoke trapezius contractions and shoulder movement but was set below the level that participants reported as uncomfortable.

Bilateral exercise

Participants first warmed up for 5 minutes by pedalling an arm ergometer at approximately 50 rpm against minimal resistance, then performed light stretches and ROM exercises for an additional 4–5 minutes. The treatment exercises consisted of bilateral scapular retraction

(horizontal rows to isolate middle trapezius) and elevation (shoulder shrugs to isolate upper trapezius). Bilateral movements increase cortical excitability more than unilateral movements and maximise the potential for strengthening corticospinal pathways,²⁴ particularly when combined with NMES.²⁵ Participants were seated and exercised using moderate–strong tubing for resistance. The primary focus was on improving scapular stability and positioning by strengthening the weakened trapezius muscle in its inner range. Treatment began (at baseline) with 2 sets of 5 repetitions for each exercise with 2 minute rests between sets. Participants were progressed by increasing first repetitions (e.g., 6–12) and then sets (e.g., 2–3), depending on the quality of movement and muscle contraction and the participant's agreement to progression.

RESULTS

Treatments were completed with 100% adherence. All participants increased their workload from 2 sets of 5 repetitions of each exercise at baseline to 3 sets of 12 repetitions by week 6. ROM measurement results for each participant are provided in Table 1. Flexion and abduction increases were observed in all participants after 6 weeks, but only Patient 1 demonstrated changes greater than the MCID¹⁰ values for both movements. SPADI and NDII scores are shown in Table 2. Although SPADI scores improved for all participants, the MCID of 10 points¹² was not met by any participant. NDII scores also improved for all patients.

DISCUSSION

This case series describes the outcomes of three patients who participated in a rehabilitation program combining NMES and bilateral exercise to improve trapezius muscle function after surgery for head and neck cancer. The most clinically relevant observation was the improvement in ROM. Shoulder dysfunction in this patient group was due to reduced voluntary control of the trapezius muscle, which resulted from damage to the SAN during surgery. During movement, the trapezius plays a major role in stabilizing and controlling the scapula; reduced trapezius strength disrupts the biomechanics of scapular movement, resulting in reduced shoulder ROM and increased shoulder pain.²⁶ Greater trapezius control will improve upward rotation of the scapula, scapulohumeral rhythm, and shoulder ROM.²⁷

All participants had received extensive physical therapy before taking part in the study, and all reported low baseline levels of pain and dysfunction on the SPADI scale, which measures shoulder pain and dysfunction associated with activities of daily living. The NDII examines the impact of neck dissection on QOL and includes items related to work and recreational activities; although no MCID has been established for the NDII, improvements in patient scores suggest decreases in perceived

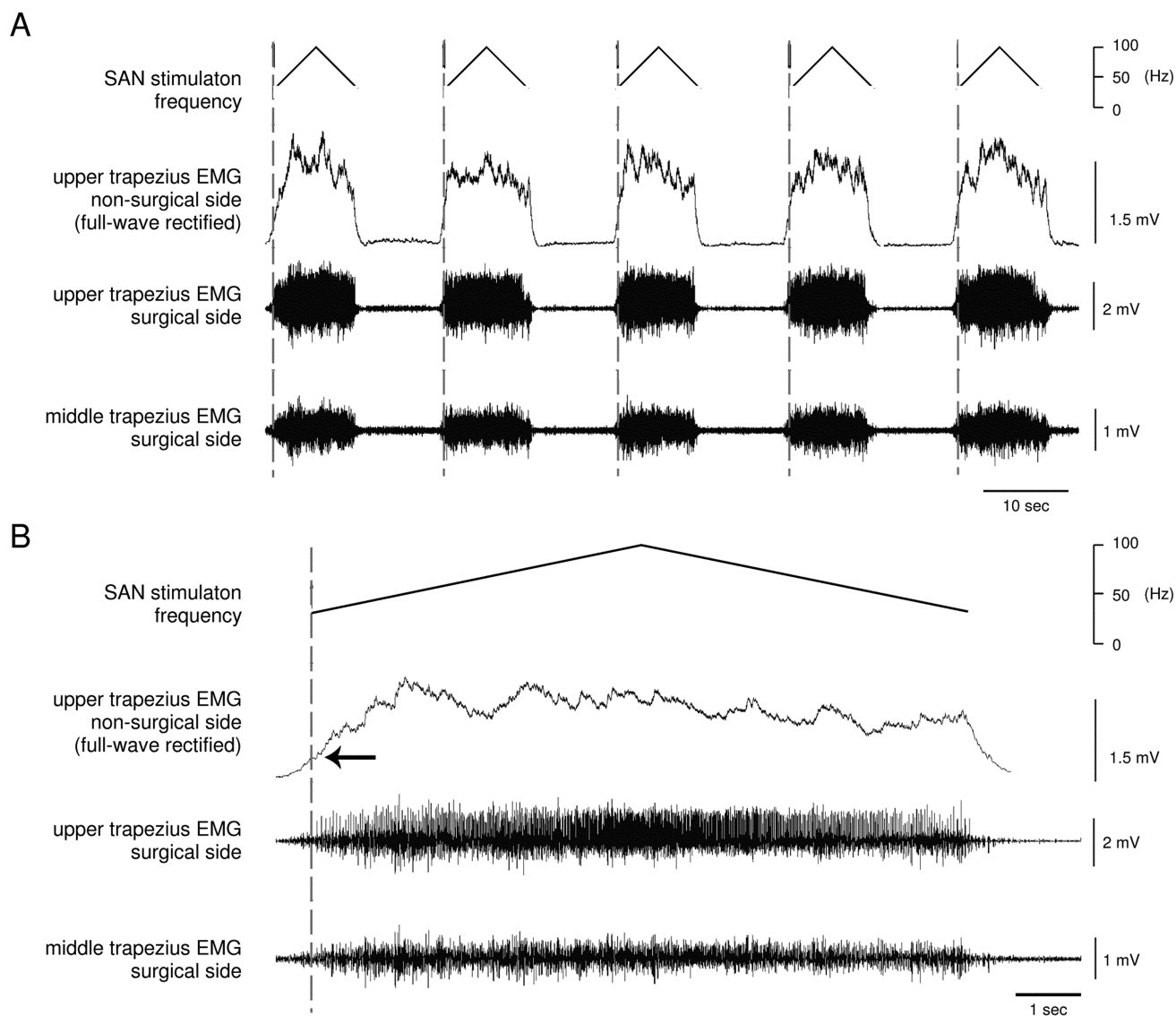


Figure 2 Electromyographic activity and the timing and frequency of the stimulation during shoulder elevation exercises.

pain and disability.¹³ Shoulder pain after head and neck dissection surgery is thought to arise from a multitude of factors including muscle imbalance, impingement, and poor recruitment patterns around the shoulder complex which alter scapular position and scapulohumeral rhythm.²⁸ Thus, increased strength of the trapezius muscle will lead to improvements in scapular resting position, thereby reducing pain from the surrounding tissues. As Patient 3's results show, reductions in pain and improvements in QOL may result independent of improvements in ROM.

We combined bilateral exercise and NMES to address central and peripheral mechanisms that can contribute to persistent trapezius dysfunction. At the level of the muscle, contractions evoked by NMES reduce muscle atrophy.¹⁹ Delivering NMES to enhance the extent to which pathways through the spinal cord contribute to

the evoked contractions, as in the present study, may further reduce muscle atrophy by preferentially activating fatigue-resistant motor units, which are most vulnerable to developing disuse atrophy.^{16–18,21} NMES also invokes changes centrally, as the electrically evoked sensory volley travels to regions in the spinal cord^{16–18,20,29} and brain^{22,23,30,31} that control the stimulated muscle. Increased excitability of corticospinal circuits is associated with improved function following NMES rehabilitation programs.³² In our study, NMES was delivered using wider pulse widths¹⁸ and higher frequencies^{21,22} than are typically used, with the goal of enhancing the electrically evoked sensory volley, which in turn may enhance plastic changes in the CNS and further strengthen corticospinal pathways.¹⁶

We incorporated bilateral exercise to augment cortical activation induced by NMES. Bilateral voluntary move-

Table 1 Average Scores of Two Raters for ROM Outcomes

| Patient | ROM, degrees | | | | |
|------------------|---------------------|------|-------------------|------|---------------|
| | Unaffected shoulder | | Affected shoulder | | Change score* |
| | Baseline | 6-wk | Baseline | 6-wk | |
| Patient 1 | | | | | |
| Active flexion | 150 | 157 | 109 | 134 | 25 |
| Active abduction | 180 | 180 | 75 | 100 | 25 |
| Patient 2 | | | | | |
| Active flexion | 153 | 154 | 111 | 121 | 10 |
| Active abduction | 159 | 163 | 101 | 111 | 10 |
| Patient 3 | | | | | |
| Active flexion | 153 | 156 | 120 | 128 | 8 |
| Active abduction | 172 | 173 | 70 | 78 | 8 |

*Change over 6-wk intervention period in the affected shoulder.
ROM = range of motion.

Table 2 Results for Patient-Rated Outcomes

| Patient | Outcome | | |
|-------------------|----------|-------------------|-------------------------|
| | Baseline | Post-intervention | Change baseline to post |
| Patient 1 | | | |
| SPADI score, /100 | 5.5 | 0.5 | -5 |
| NDII score, /100 | 62.5 | 82.5 | 20 |
| Patient 2 | | | |
| SPADI score, /100 | 17.0 | 13.5 | -3.5 |
| NDII score, /100 | 47.5 | 55 | 7.5 |
| Patient 3 | | | |
| SPADI score, /100 | 16.5 | 9.0 | -7.5 |
| NDII score, /100 | 45 | 67.5 | 22.5 |

Note: Higher SPADI scores reflect more pain and disability; higher NDII scores reflect better neck dissection associated quality of life, SPADI = Shoulder Pain and Disability Index; NDII = Neck Dissection Impairment Index.

ments produce stronger cortical activation than unilateral movements.²⁴ This enhanced activity provides part of the rationale behind the bilateral movement therapies currently showing promise for rehabilitation of people recovering from stroke.^{24,25} Given the central effects observed after NMES and bilateral training,³⁰ it is plausible this combined therapy led to a strengthening of corticospinal pathways controlling the trapezius and contributed to the improved outcomes in our study. In a post-stroke population, patients who received NMES coupled with bilateral movements demonstrated greater improvements in motor function than either those who underwent unilateral training with NMES or controls who received neither treatment.²⁵ Although our study was not designed to identify whether improvements were due to changes in peripheral or in central structures, this combined therapy shows promise for rehabilitation of movement disorders with contributions from mechanisms both in the periphery and the CNS.

This case series was the first study of any kind to combine wide-pulse width, high-frequency NMES with bilateral exercise for rehabilitation of patients with persistent trapezius dysfunction following surgery for head and neck cancer. Although our findings are promising, they are limited by the small number of eligible subjects, the relatively short duration of the intervention, and the lack of more extensive electrodiagnostic testing (i.e., needle EMG). Moreover, expanding the protocol to include strengthening of the lower trapezius muscle might have been helpful to address limitations in abduction ROM. Further research will be required to determine both the efficacy of this therapy for rehabilitation and the mechanisms behind any therapeutic outcomes. Despite these limitations, however, the approach described here may be useful as a component of a comprehensive rehabilitation program for these patients and others with injuries to peripheral and central structures.

KEY MESSAGES

What is already known on this topic

Shoulder function is often compromised in patients who have undergone surgery for head and neck cancer. The diminished function may result from traction and devascularization of the SAN during the neck dissection procedure, which can denervate the trapezius muscle. Unfortunately, in some patients, trapezius muscle dysfunction persists even after conduction along the SAN returns and this presents a challenge for rehabilitation. Traditional physical therapy interventions for these patients focus on pain management, range of motion, and progressive resistance exercise therapy. However, programs that combine NMES and bilateral movements have been shown to reduce muscle atrophy and strengthen pathways between the brain and skeletal muscles but such programs have not previously been used to restore shoulder function after surgery for head and neck cancer.

What this study adds

This prospective case series is the first study that describes an intervention involving a combination of wide pulse-width, high-frequency NMES with bilateral exercise for patients presenting with persistent trapezius dysfunction despite the return of conduction along the SAN. This novel form of NMES was used to help reduce muscle atrophy and enhance the electrically-evoked sensory volley sent to the CNS to increase the activity and excitability in sensorimotor pathways. Bilateral voluntary movements were used to further augment the activity and excitability in CNS circuits. All patients showed improvements in shoulder flexion and abduction ROM and reported reductions in pain and disability. This combination of NMES and bilateral exercise may prove to be an effective component of a comprehensive shoulder rehabilitation program for patients with persistent trapezius muscle dysfunction as a result of SAN damage, and perhaps also for patients with damage to other sensorimotor pathways.

REFERENCES

- McGarvey AC, Chiarelli PE, Osmotherly PG, et al. Physiotherapy for accessory nerve shoulder dysfunction following neck dissection surgery: a literature review. *Head Neck*. 2011;33(2):274–80. <http://dx.doi.org/10.1002/hed.21366>. Medline:20222043
- Shimada Y, Chida S, Matsunaga T, et al. Clinical results of rehabilitation for accessory nerve palsy after radical neck dissection. *Acta Otolaryngol*. 2007;127(5):491–7. <http://dx.doi.org/10.1080/00016480600895151>. Medline:17453475
- Umeda M, Shigeta T, Takahashi H, et al. Shoulder mobility after spinal accessory nerve-sparing modified radical neck dissection in oral cancer patients. *Oral Surg Oral Med Oral Pathol Oral Radiol Endod*. 2010;109(6):820–4. <http://dx.doi.org/10.1016/j.tripleo.2009.11.027>. Medline:20299249
- Erisen L, Basel B, Irdesel J, et al. Shoulder function after accessory nerve-sparing neck dissections. *Head Neck*. 2004;26(11):967–71. <http://dx.doi.org/10.1002/hed.20095>. Medline:15459926
- van Wilgen CP, Dijkstra PU, van der Laan BF, et al. Shoulder complaints after neck dissection; is the spinal accessory nerve involved? *Br J Oral Maxillofac Surg*. 2003;41(1):7–11. [http://dx.doi.org/10.1016/S0266-4356\(02\)00288-7](http://dx.doi.org/10.1016/S0266-4356(02)00288-7). Medline:12576033
- McNeely ML, Parliament MB, Seikaly H, et al. Effect of exercise on upper extremity pain and dysfunction in head and neck cancer survivors: a randomized controlled trial. *Cancer*. 2008;113(1):214–22. <http://dx.doi.org/10.1002/cncr.23536>. Medline:18457329
- Kraft GH. Fibrillation potential amplitude and muscle atrophy following peripheral nerve injury. *Muscle Nerve*. 1990;13(9):814–21. <http://dx.doi.org/10.1002/mus.880130907>. Medline:2233867
- Navarro X, Vivó M, Valero-Cabré A. Neural plasticity after peripheral nerve injury and regeneration. *Prog Neurobiol*. 2007;82(4):163–201. <http://dx.doi.org/10.1016/j.pneurobio.2007.06.005>. Medline:17643733
- Low JL. The reliability of joint measurement. *Physiotherapy*. 1976;62(7):227–9. Medline:967944
- Muir SW, Corea CL, Beaupre L. Evaluating change in clinical status: reliability and measures of agreement for the assessment of glenohumeral range of motion. *N Am J Sports Phys Ther*. 2010;5(3):98–110. Medline:21589666
- Heald SL, Riddle DL, Lamb RL. The shoulder pain and disability index: the construct validity and responsiveness of a region-specific disability measure. *Phys Ther*. 1997;77(10):1079–89. Medline:9327822
- Williams JW Jr, Holleman DR Jr, Simel DL. Measuring shoulder function with the shoulder pain and disability index. *J Rheumatol*. 1995;22(4):727–32. Medline:7791172
- Taylor RJ, Chepeha JC, Teknos TN, et al. Development and validation of the neck dissection impairment index: a quality of life measure. *Arch Otolaryngol Head Neck Surg*. 2002;128(1):44–9. Medline:11784253
- Kraemer WJ, Fleck SJ, Evans WJ. Strength and power training: physiological mechanisms of adaptation. *Exerc Sport Sci Rev*. 1996;24:363–97. Medline:8744256
- Garber CE, Blissmer BB, Deschenes MR, et al; American College of Sports Medicine. American College of Sports Medicine position stand. Quantity and quality of exercise for developing and maintaining cardiorespiratory, musculoskeletal, and neuromotor fitness in apparently healthy adults: guidance for prescribing exercise. *Med Sci Sports Exerc*. 2011;43(7):1334–59. <http://dx.doi.org/10.1249/MSS.0b013e318213febf>. Medline:21694556
- Bergquist AJ, Clair JM, Lagerquist O, et al. Neuromuscular electrical stimulation: implications of the electrically evoked sensory volley. *Eur J Appl Physiol*. 2011;111(10):2409–26. <http://dx.doi.org/10.1007/s00421-011-2087-9>. Medline:21805156
- Baldwin ER, Klakowicz PM, Collins DF. Wide-pulse-width, high-frequency neuromuscular stimulation: implications for functional electrical stimulation. *J Appl Physiol*. 2006;101(1):228–40. <http://dx.doi.org/10.1152/jappphysiol.00871.2005>. Medline:16627680
- Bergquist AJ, Clair JM, Collins DF. Motor unit recruitment when neuromuscular electrical stimulation is applied over a nerve trunk compared with a muscle belly: triceps surae. *J Appl Physiol*. 2011;110(3):627–37. <http://dx.doi.org/10.1152/jappphysiol.01103.2010>. Medline:21183628
- Sheffler LR, Chae J. Neuromuscular electrical stimulation in neuro-rehabilitation. *Muscle Nerve*. 2007;35(5):562–90. <http://dx.doi.org/10.1002/mus.20758>. Medline:17299744
- Lagerquist O, Collins DF. Influence of stimulus pulse width on M-waves, H-reflexes, and torque during tetanic low-intensity neuromuscular stimulation. *Muscle Nerve*. 2010;42(6):886–93. <http://dx.doi.org/10.1002/mus.21762>. Medline:20886511
- Dean JC, Yates LM, Collins DF. Turning on the central contribution to contractions evoked by neuromuscular electrical stimulation. *J Appl Physiol*. 2007;103(1):170–6. <http://dx.doi.org/10.1152/jappphysiol.01361.2006>. Medline:17463296
- Mang CS, Lagerquist O, Collins DF. Changes in corticospinal excitability evoked by common peroneal nerve stimulation depend on stimulation frequency. *Exp Brain Res*. 2010;203:11–20. <http://dx.doi.org/10.1007/s00221-010-2202-x>. Medline:20217400
- Khaslavskaiia S, Sinkjaer T. Motor cortex excitability following repetitive electrical stimulation of the common peroneal nerve depends on the voluntary drive. *Exp Brain Res*. 2005;162(4):497–502. <http://dx.doi.org/10.1007/s00221-004-2153-1>. Medline:15702321
- Cauraugh JH, Summers JJ. Neural plasticity and bilateral movements: a rehabilitation approach for chronic stroke. *Prog Neurobiol*. 2005;75(5):309–20. <http://dx.doi.org/10.1016/j.pneurobio.2005.04.001>. Medline:15885874
- Cauraugh JH, Kim S. Two coupled motor recovery protocols are better than one: electromyogram-triggered neuromuscular stimulation and bilateral movements. *Stroke*. 2002;33(6):1589–94. <http://dx.doi.org/10.1161/01.STR.0000016926.77114.A6>. Medline:12052996
- Bagg SD, Forrest WJ. Electromyographic study of the scapular rotators during arm abduction in the scapular plane. *Am J Phys Med*. 1986;65(3):111–24. Medline:3717317

27. Wang CH, McClure P, Pratt NE, et al. Stretching and strengthening exercises: their effect on three-dimensional scapular kinematics. *Arch Phys Med Rehabil.* 1999;80(8):923–9. [http://dx.doi.org/10.1016/S0003-9993\(99\)90084-9](http://dx.doi.org/10.1016/S0003-9993(99)90084-9). Medline:10453769
28. Magarey ME, Jones MA. Dynamic evaluation and early management of altered motor control around the shoulder complex. *Man Ther.* 2003;8(4):195–206. [http://dx.doi.org/10.1016/S1356-689X\(03\)00094-8](http://dx.doi.org/10.1016/S1356-689X(03)00094-8). Medline:14559042
29. Thompson AK, Doran B, Stein RB. Short-term effects of functional electrical stimulation on spinal excitatory and inhibitory reflexes in ankle extensor and flexor muscles. *Exp Brain Res.* 2006;170(2):216–26. <http://dx.doi.org/10.1007/s00221-005-0203-y>. Medline:16317575
30. Hoffman LR, Field-Fote EC. Cortical reorganization following bimanual training and somatosensory stimulation in cervical spinal cord injury: a case report. *Phys Ther.* 2007;87(2):208–23. <http://dx.doi.org/10.2522/ptj.20050365>. Medline:17213410
31. Charlton CS, Ridding MC, Thompson PD, et al. Prolonged peripheral nerve stimulation induces persistent changes in excitability of human motor cortex. *J Neurol Sci.* 2003;208(1-2):79–85. [http://dx.doi.org/10.1016/S0022-510X\(02\)00443-4](http://dx.doi.org/10.1016/S0022-510X(02)00443-4). Medline:12639729
32. Everaert DG, Thompson AK, Chong SL, et al. Does functional electrical stimulation for foot drop strengthen corticospinal connections? *Neurorehabil Neural Repair.* 2010;24(2):168–77. <http://dx.doi.org/10.1177/1545968309349939>. Medline:19861590